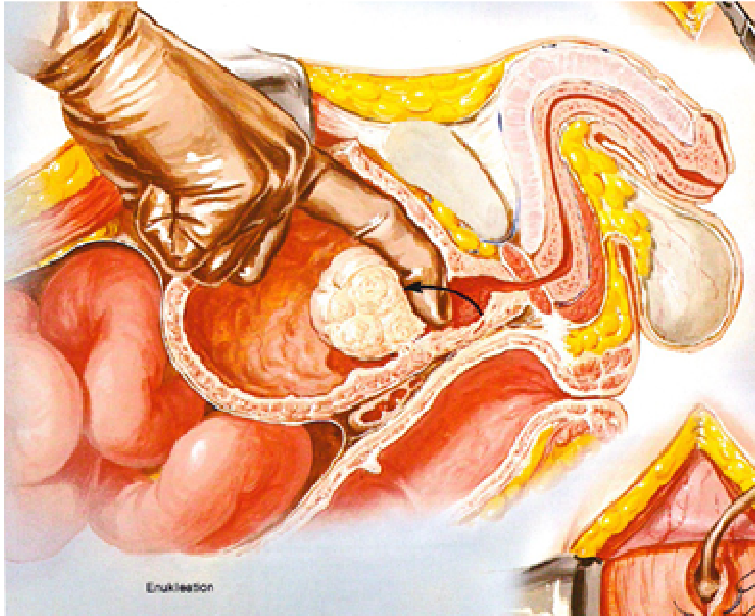


Abb. „Transvesikale Adenomenukleation“



Transvesikale Adenomenukleation

Farbatlanten der Medizin / Netter, offene Adenektomie / Enukleation