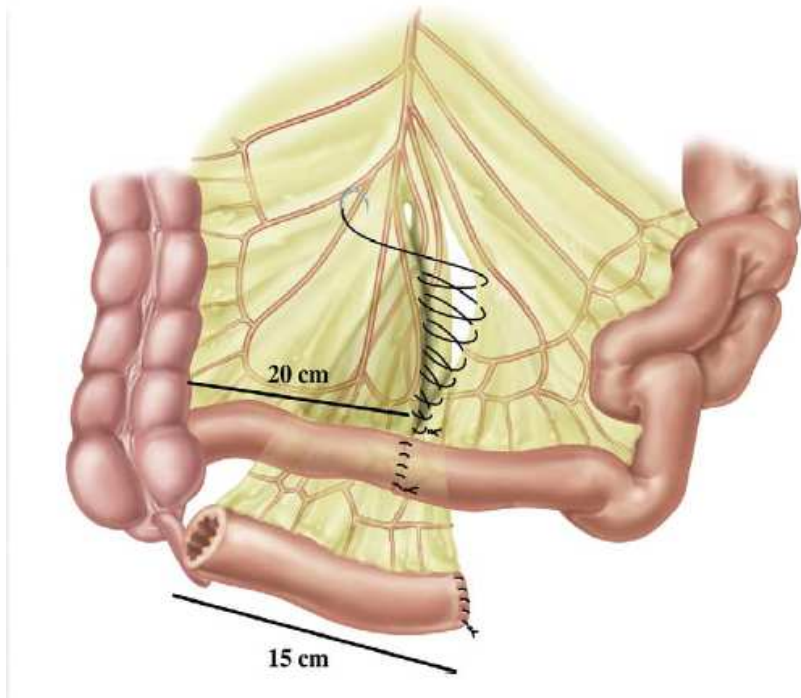
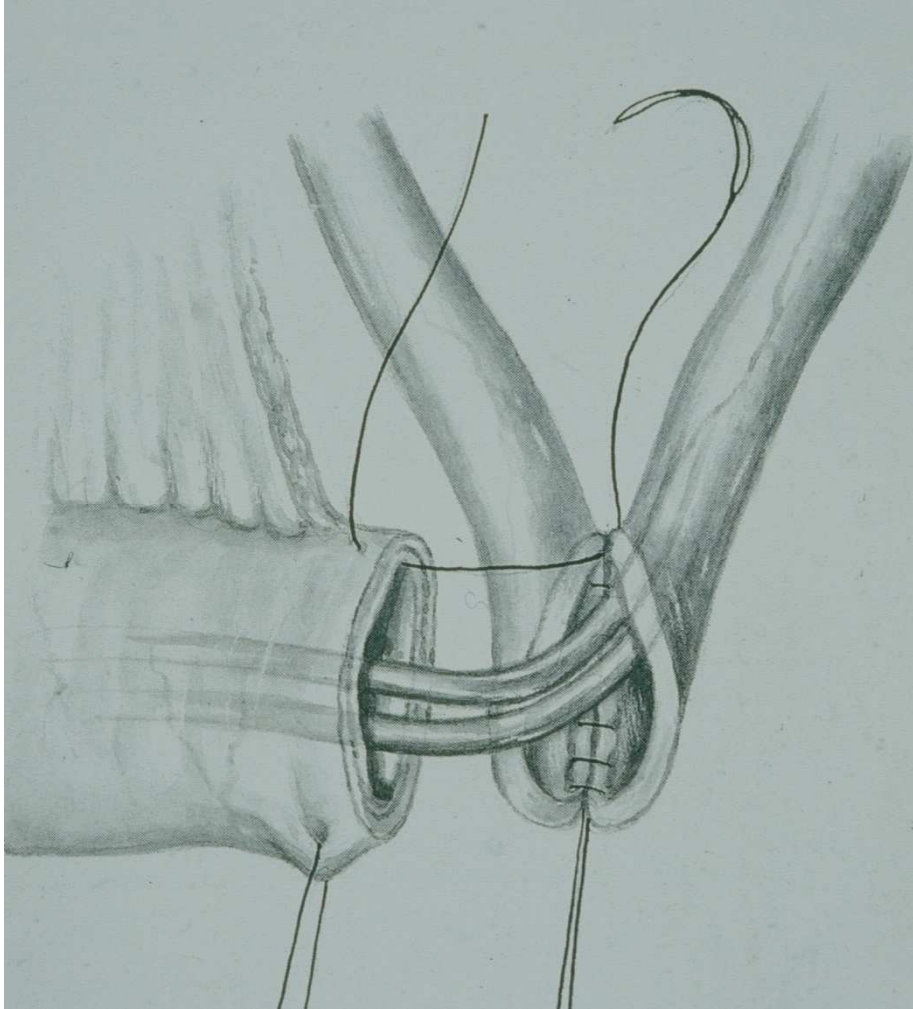


Abb. Ileum-Conduit



a) Isolation von 15 cm Dünndarm

Abb. aus:
Colombo, et al www.europeanurology.com



b) Wallace Anastomose zwischen Harnleiter und oberem Ende des Conduits